

Excision of Prominent Posterior Septal Angle and Nasal Spine for Downward Tip Rotation, in Short Upper Lip, or Over-Rotated Tip

Nikolay P. Serdev *

New Bulgarian University, Sofia, Medical Centre "Aesthetic Surgery and Aesthetic Medicine", Sofia, Bulgaria

Abstract: The author uses resection of the posterior septal angle and nasal spine for downward tip rotation in cases of obtuse nasolabial angle and a short upper lip [1-5]. It could be an independent procedure or part of T-excision, or other type of primary or secondary rhinoplasty. This excision is easy to perform, prolonging the retro-columellar incision downward. A 2-3 mm excision of the length of the caudal septum in the part of the posterior septal angle, (incl. the spina nasalis anterior) may be enough to shorten the length of the nasal pyramid at its base and adapt the long pyramid to the aesthetic middle third of the face. This is helpful, especially in women with delicate faces and unproportional noses. This procedure is mini-invasive, nearly bloodless, does not require tampons, bandages. There is almost no downtime.

Keywords: Rhinoplasty; excision; posterior septal angle; nasal spine; miniinvasive technique; long nose; elongated septum; over rotated tip; short upper lip; primary or secondary; retrocolumellar incision; no bandages; no downtime.

INTRODUCTION

If the upper lip is shortened by a too long septum, or if shortening of the longer nasal pyramid is necessary, the prominent posterior septal angle can be excised, together with the anterior nasal spine [4]. This maneuver

deepens the nasolabial angle and can be used also in cases of over-rotated tip (obtuse tip).

ANATOMY

***Address correspondence to Nikolay P. Serdev:** New Bulgarian University, Sofia, Medical Centre “Aesthetic Surgery and Aesthetic Medicine”, Sofia, Bulgaria; E-mail: serdev@gmail.com,

Ricardo Dias, Antonio A. Martins, Rui Lima and Teresa M. Mata (Eds)
All rights reserved-© 2012 Bentham Science Publishers

The length of the nasal pyramid should occupy the middle third of the face. Longer pyramid should be shortened, if unproportional to the face. This could happen when reducing the prominent posterior septal angle and the prominence of the anterior nasal spine.

In long and aquiline noses the facial proportions are imbalanced. Often, except the elongation of the caudal septum, the nasal pyramid (incl. the posterior septal angle) and nasal spine can also be elongated with shortening of the upper lip. In these cases cephalic strip excision alone does not suffice to shorten the elongated nasal pyramid.

Vice versa, in Asian and Afro-American noses, as well as in some secondary iatrogenic cases, the tip can be over-rotated with an obtuse nasolabial angle, which could be a good indication for excision of the prominent posterior septal angle and anterior nasal spine.

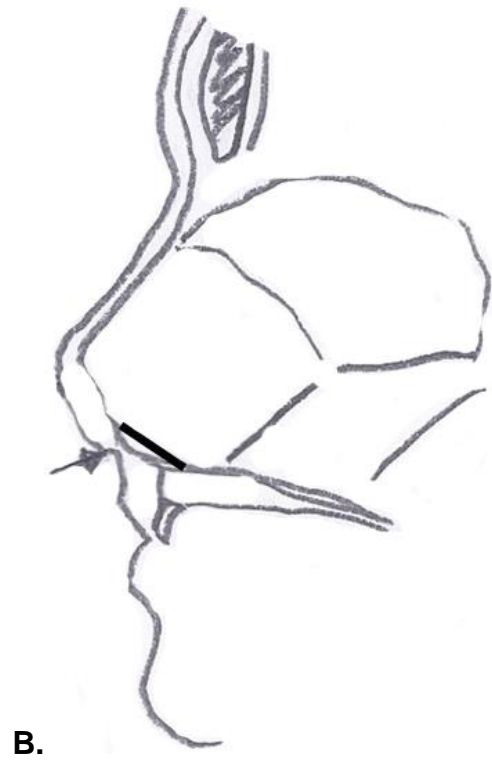
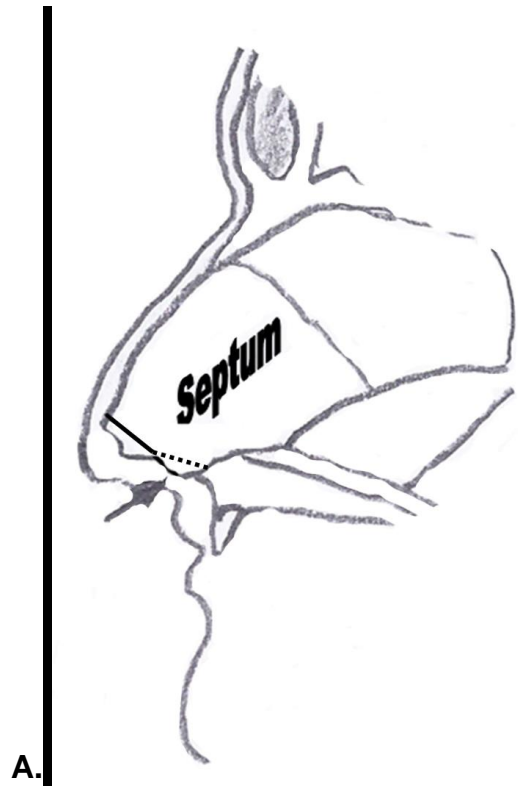

Figure 1.A: Long aquiline nose, Short upper lip, elongated septal cartilage and nasal pyramid. Author's T-excision, or cephalic strip excision and caudal septal shortening could help in this case, together with posterior septal angle and nasal spine resection (marked) to elongate the upper lip. **B.** Ethnic (Asian or Afro-American) or iatrogenic obtuse nasolabial angle with over-rotated tip. Precise excision of the posterior septal angle and nasal spine (marked) can help to correct the nasolabial and tip angle.

INDICATIONS

Ethnic aquiline long noses with elongated nasal pyramid as well as ethnic (Asian or Afro-American) or iatrogenic over-rotated tip with obtuse nasolabial angle.

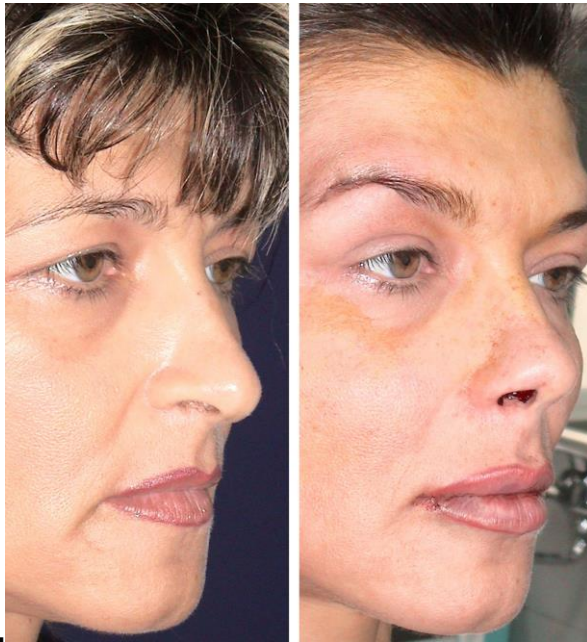SURGICAL TECHNIQUE

It is an outpatient technique under local anesthesia. It could be performed as an independent procedure in cases of iatrogenic or ethnic over-rotated tips as well as in case of long or aquiline noses.

In all cases, a retrocolumellar incision is performed, which will be prolonged downwards to excise about 2, rarely 3 mm of the posterior septal angle together with the anterior nasal spine.

The author fixes the columella to the septum with transmucosal mattress sutures, which remain for 2-3 weeks. No bandages or tampons are necessary for this separate procedure. It is mini-invasive, atraumatic and bloodless.

CLINICAL CASES



A. **B.**
Figure 2: A. Before. Long nose and proportionally shortened upper lip. **B.** Immediately after T-excision for tip rotation to obtain correct aesthetic proportions of the face, combined with a 2 mm excision of the prominent posterior septal angle and nasal spine (for elongation of the upper lip and achieving a correct proportion of the lower face). Simultaneous brow lift and lip augmentation. The picture is taken in the operation room. The face is still not cleaned from the Braunol disinfection.



A. **B.**

Figure 3: A. Before. Ethnic long and aquiline nose, disrupting the correct facial proportions. Short upper lip, with incorrect 3:1 proportion of the lower face. **B.** After. Rhinoplasty, including humpectomy, digital fracture vs lateral osteotomy, T-excision for tip rotation and 3 mm excision of the prominent posterior septal angle and nasal spine. The result is correct aesthetic proportions of the face and lower third of the face. The photo is taken in the operation theatre, immediately after ambulatory closed rhinoplasty - atraumatic, mini-invasive, bloodless. The result is beautification.



A. **Figure 4: A.** Before. Ethnic long and aquiline nose disrupting the correct facial proportions. No self-confidence, uncertain appearance. Short upper lip. **B.** After. Rhinoplasty, including humpectomy, digital fracture vs lateral osteotomy, T-excision for tip rotation and 3 mm excision of the prominent posterior septal angle and nasal spine to improve the lower third of the face. The result is beautification and improved self-confidence.

CONCLUSION

Excision of caudal septum in long noses, combined with excision of prominent posterior septal angle and nasal spine, is a very effective technique. It is of great help in cases of longer caudal septum and nasal pyramid with a short upper lip, as well as in cases of over-rotated noses. The procedure helps to adapt the face to correct aesthetic proportions, which is the main goal in beautification. The technique itself is time saving, atraumatic and also very well tolerated by patients, with no downtime and immediate return to work and social life.

REFERENCES

- [1] Serdev NP. Sliding of the columella by the Serdev Technique, Live Surgery Workshop, The International Academy of Aesthetic Surgery and Aesthetic Medicine, Krulig Clinic, Caracas, Venezuela, Nov 1999
- [2] Serdev NP. Principles of Face Beautification, 3rd World Congress of the International Society of Aesthetic Surgery, Tokyo April 8-10, 2000
- [3] Serdev NP. Rhinoplasty for beautification. Asia Pacific Craniofacial Association. Third Conference, Shanghai, P.R. China, Oct. 30th – Nov. 1st, 2000
- [4] Serdev NP. Beautification rhinoplasty. Int J Cosm Surg 2006; 6(1): 1-53
- [5] Serdev NP. Course: Beautification rhinoplasty, t-zone excision, columella sliding, suture methods, Updates in IV sedation and analgesia. 2005; Feb 23. Available from: <http://ijcs.org/courses/2005/90/index.php>